

MEMBRANE PRE-CARICATE PER INTERVENTI DI DMEK

Alessandro Ruzza

XX Congresso Nazionale S.I.TRA.C
25-27 febbraio 2016 - Rimini

DISCLOSURE

This study was supported by

Eye Bank Association of America (EBAA) 2014 Richard Lindstrom Research Grant and *Società Oftalmologica Italiana (SOI)* to Diego Ponzin, MD (Director – FBOV, Italy)

Prof. Massimo Busin received travel reimbursement from Moria, Antony, France

None of the authors have any potential conflict of interest

PRE-STRIPPED membrane for DMEK

- n= 229 (from May 2014)
 - wastage: <7% (n=16)




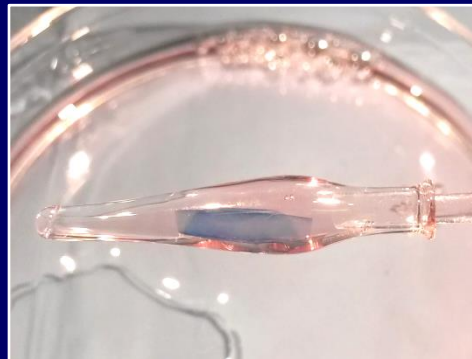
PRE-STRIPPED MEMBRANE

PRE-STRIPPED membrane for DMEK

- n= 229 (from May 2014)
 - wastage: <7% (n=16)

Pre-loaded membrane for DMEK

- Preparation and preservation
 - **MEM ± Dextran (!?)**
 - Membrane characterization
- Membrane Orientation
 - **ENDO FLAP-IN vs ENDO FLAP-OUT**



DEXTRAN VS NON DEXTRAN:

Medium combination for *in Vitro* analysis (n=20)

INITIAL
PRESERVATION

Tissue culture
medium
-
DEXTRAN

Tissue Culture
Medium
+
DEXTRAN

TCM

TCM+D




STRIPPING

FINAL
PRESERVATION
(4 days at RT)

TCM

TCM+D

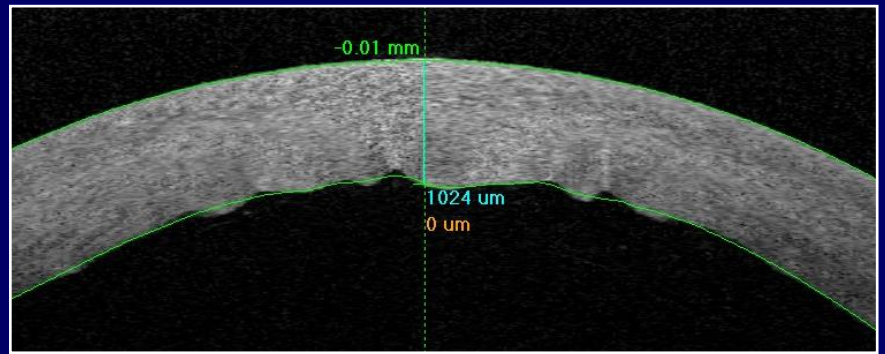


ANALYZING

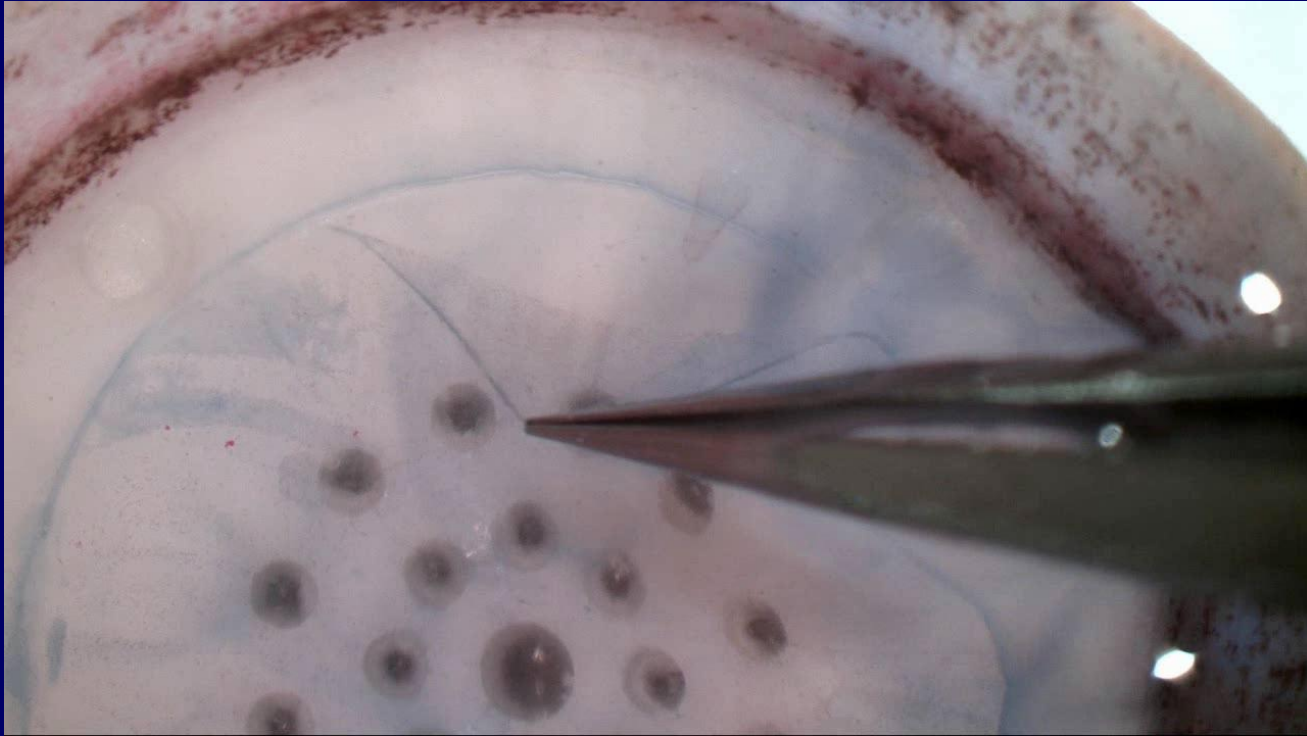
DEXTRAN VS NON DEXTRAN:

Non Dextran

- Irregular punch incision
- Ease to break membrane



OCT – cornea stored without Dextran

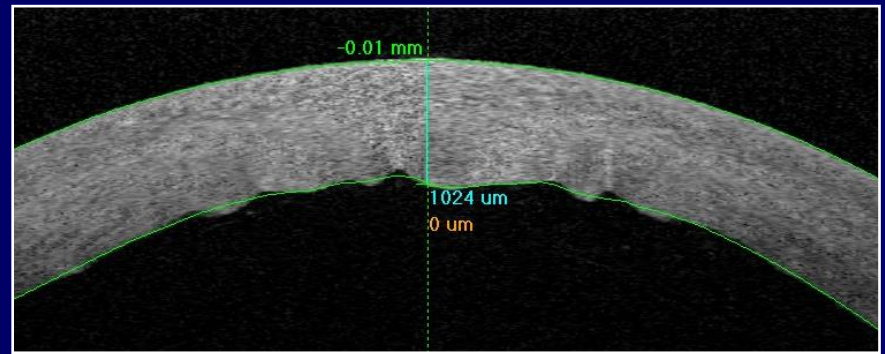


Light microscope (50x): Trypan Blue/Sucrose, peripheral membrane detachment

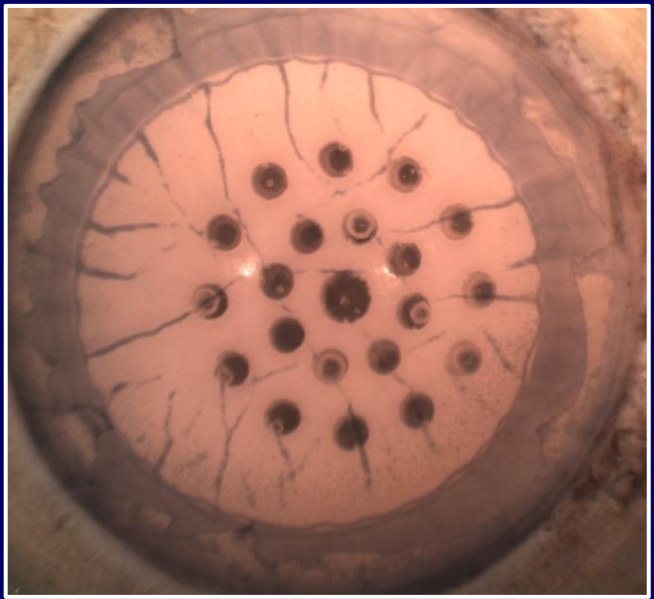
DEXTRAN VS NON DEXTRAN:

Non Dextran

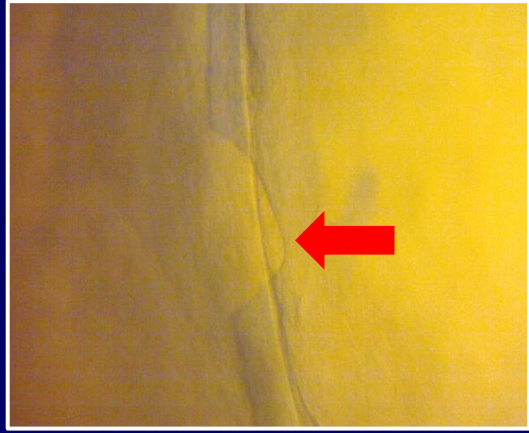
- Irregular punch incision
- ease to break membrane
- Endothelial cells detachment
 - on folds and spots



OCT – cornea stored without Dextran



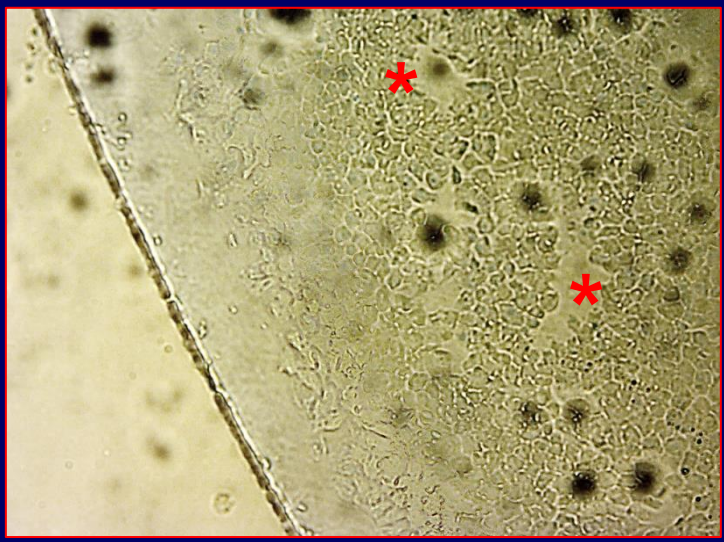
Stereo microscope (1x): Trypan Blue/PBS, after external endothelial removal and **before stripping procedure**



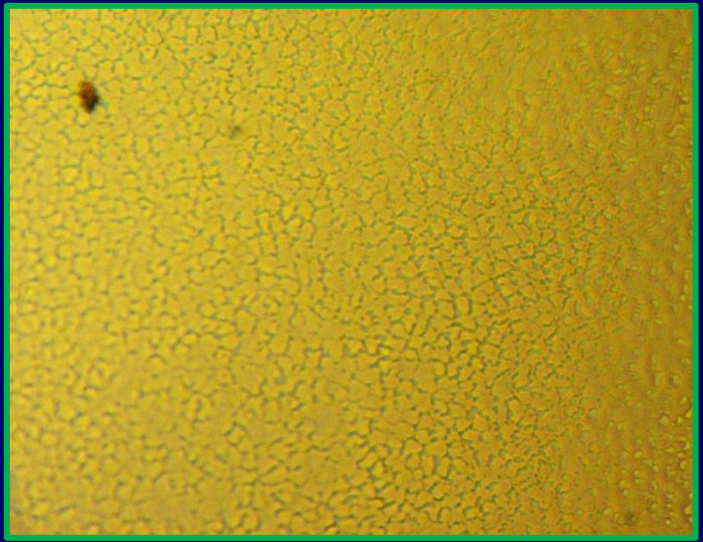
Light microscope (50x): Trypan Blue/Sucrose, peripheral membrane detachment

DEXTRAN VS NON DEXTRAN:

	- Dextran (n=10)	+ Dextran (n=10)
Success rate	7/10	10/10
Mortality	25.94(±44.23) %	3.8(±7.74) %
Uncovered areas	40.7 (±47.96) %	13.0(±18.55) %



100x – Saccarosio/Trypan Blue



100x – Saccarosio/Trypan Blue

DEXTRAN VS NON DEXTRAN:

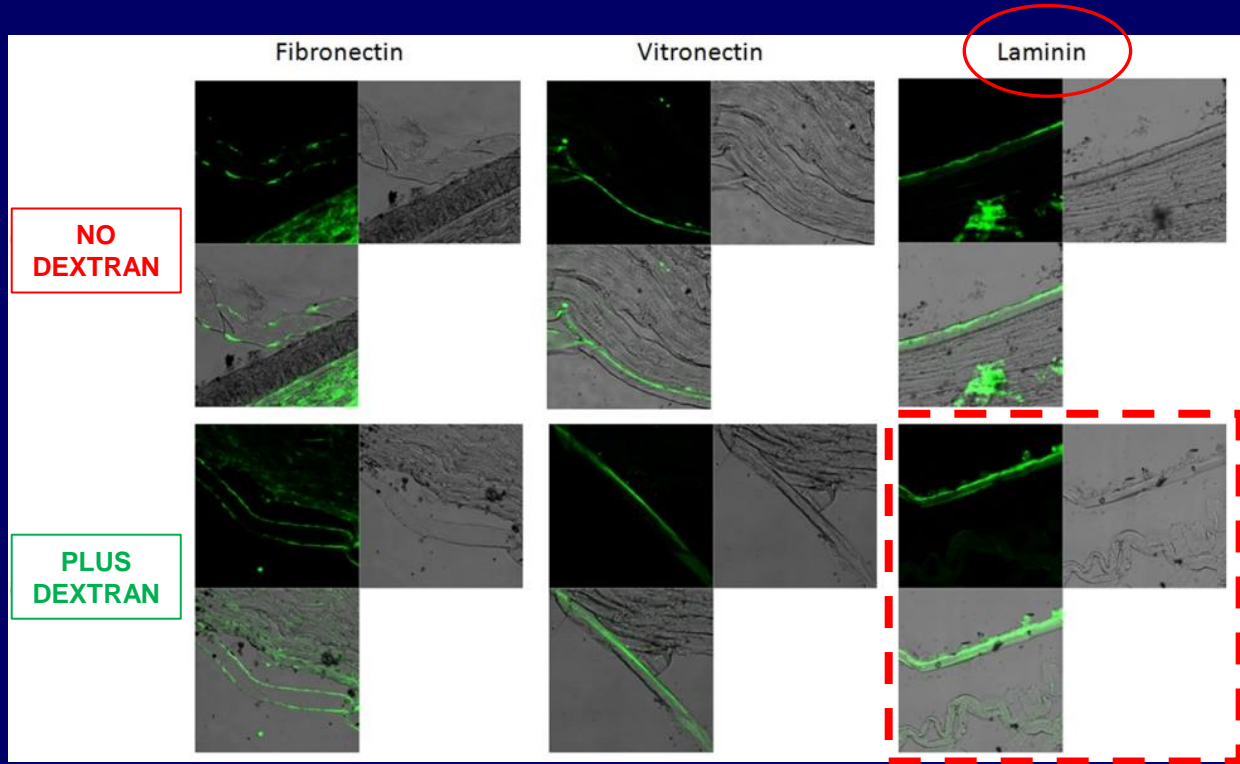
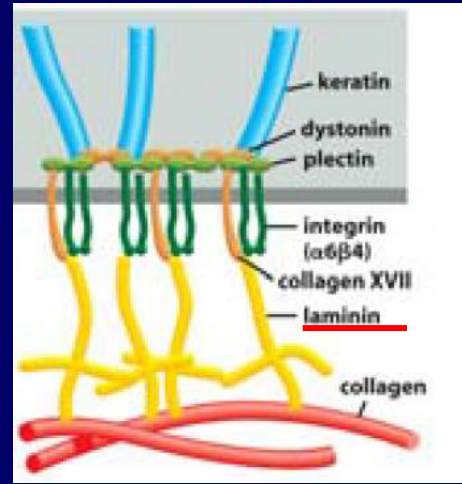
Adhesive and Elastic Proteins (n=6)

Elastic proteins:

- Fibrillin: not expressed
- Elastin: not expressed
- Collagen-VI: expr. on the post. stroma

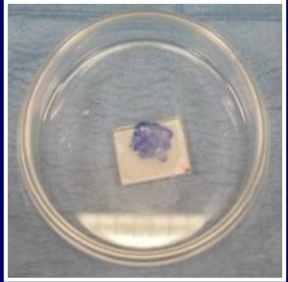
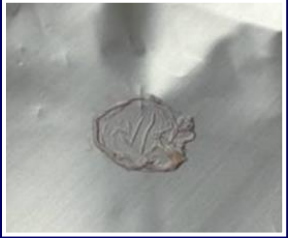Adhesive proteins:

- Fibronectin: expressed
- Vitronectin: expressed
- Laminin: highly expressed in C2
 - Hemidesmosome complex
 - Membrane strength and elasticity

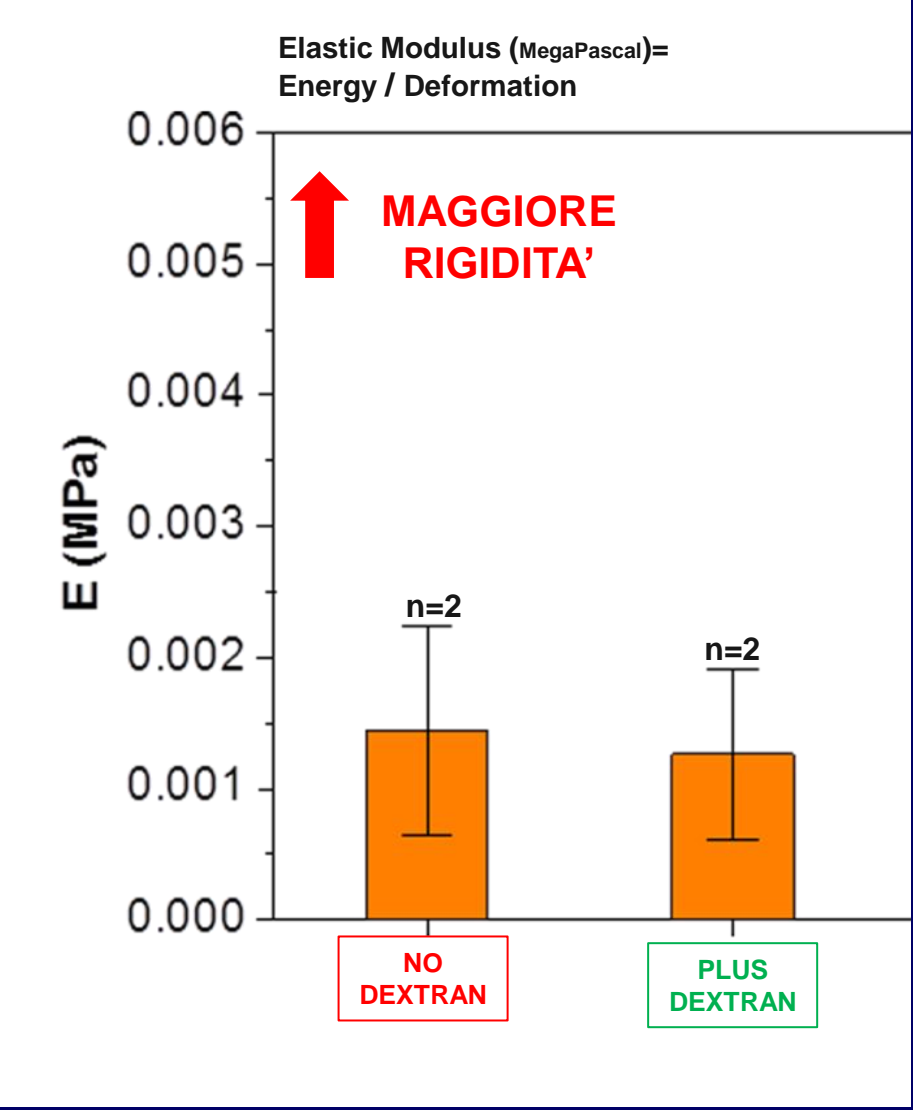
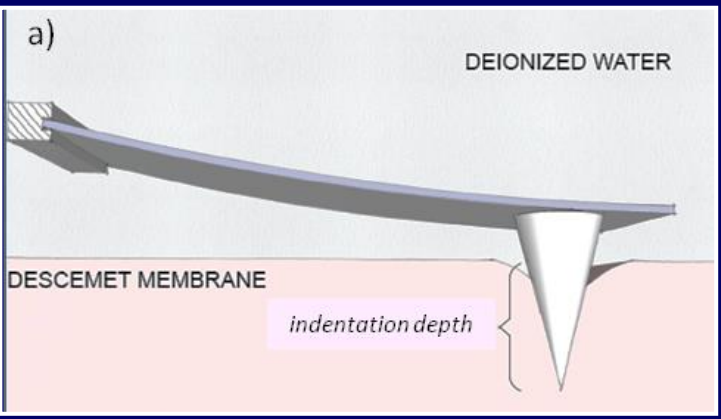


DEXTRAN VS NON DEXTRAN:

NANOINDENTATION measurements (n=6)
for BIOMECHANIC PROPERTIES

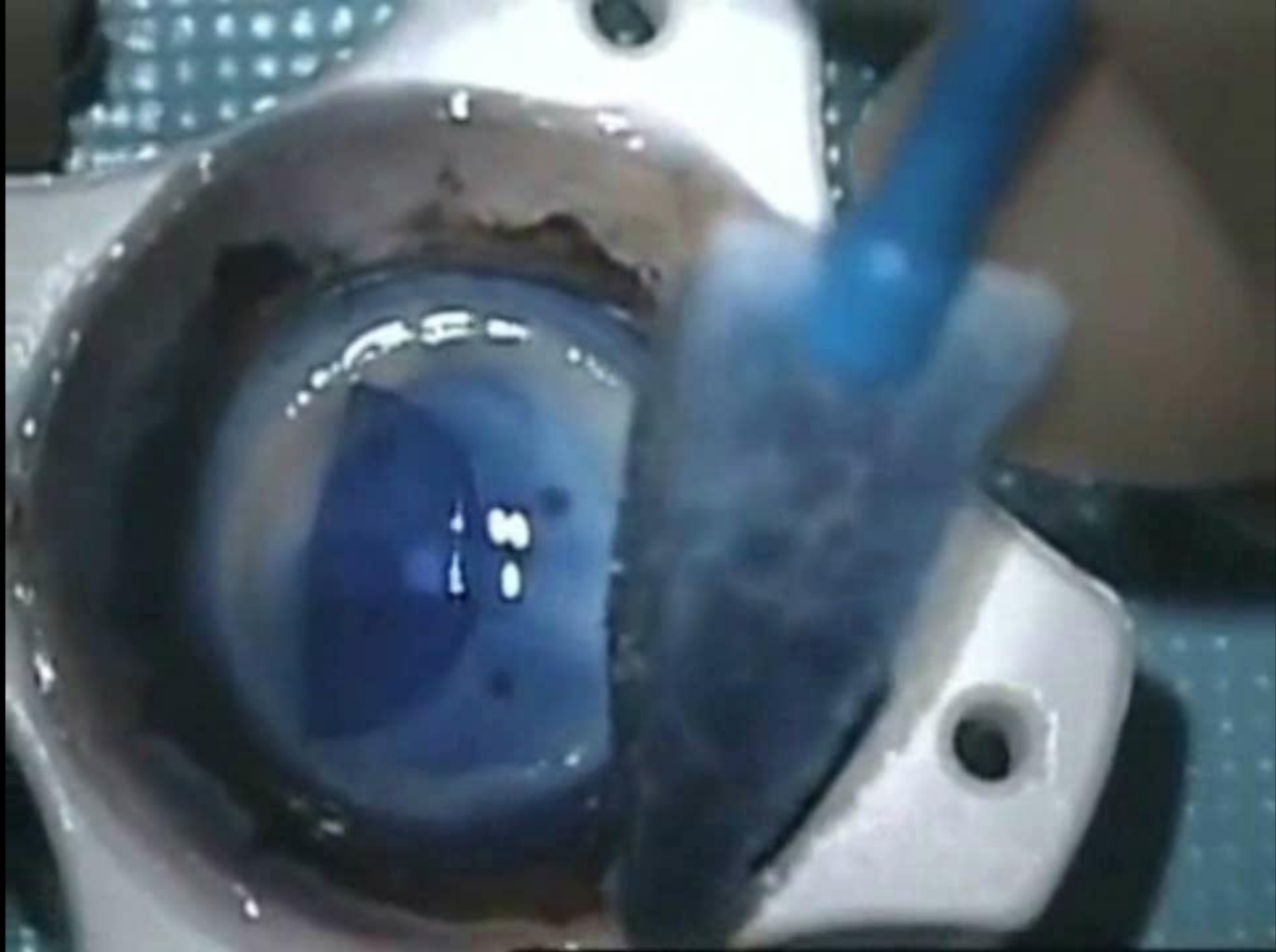


Atomic Force Microscopy



MEMBRANE ORIENTATION

ENDO-OUT Preparation and usage



MEMBRANE ORIENTATION

ENDO-IN Preparation and usage

PRE-LOADED MEMBRANE PREPARATION

ENDO-OUT vs ENDO-IN

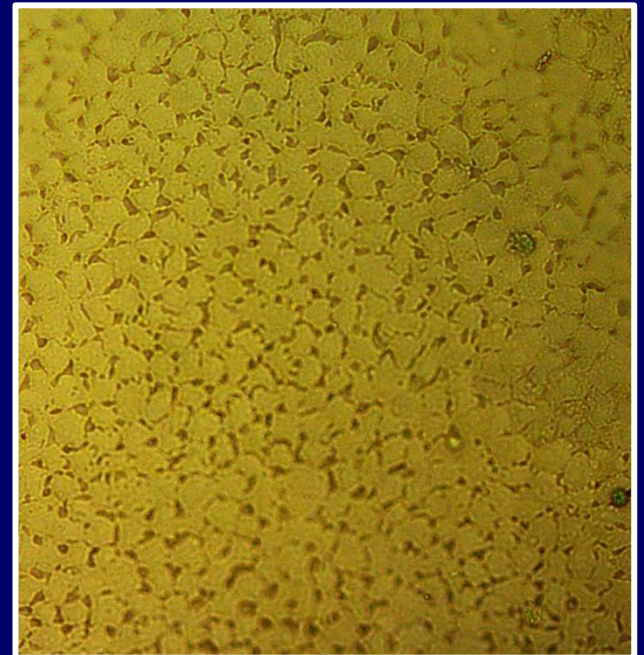
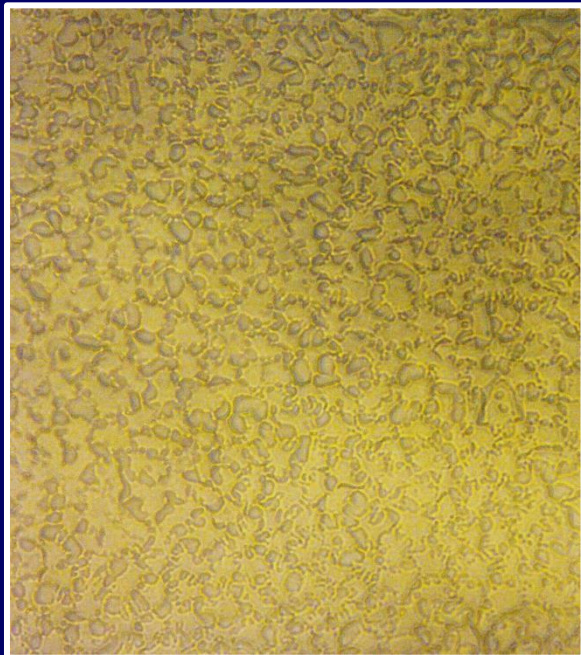
Loading and usage COMPARISON (n=18)

	ENDO-OUT (n=9)	ENDO-IN (n=9)	
Cell loss (%)	7,56	10,53	$p > 0.05$
Time to PREPARE (min)	1.68 (± 0.57)	4.43 (± 3.43)	$p = 0.0433$
Time to UNFOLD (min)	4.92 (± 4.21)	0.82 (± 1.04)	$p = 0.0194$

ENDO-IN

PRE-LOADED membrane for **4 DAYS** in the IOL cartridge (n=20)

POST-STRIPPING			POST-PRESERVATION			
Density (cell/mm ²)	Mortality (%)	Uncovered Areas (%)	Density (cell/mm ²)	Mortality (%)	Uncovered Areas (%)	Cell loss (%)
2070(±374.31)	5.08(±12.61)	0.73(±1.89)	1980(±278.34)	3.55(±5.79)	7.8(±14.13)%	4.35%



TAKE HOME MESSAGE

PRE-LOADING membrane for DMEK

- An Eye Bank **standardized procedure**
 - **ENDO-IN**: Ease to unfold by **pull through** (or Injection !?)
 - **DEXTRAN**: Maintains the tissue flexibility and **preserve cell adhesion**
- ISSUES to fix
 - Membrane orientation during the transportation
 - Trypan blue staining before usage
- A **new dedicated device** is being development
- Clinical validation is now required

THANK YOU FOR YOUR ATTENTION



Co-authors

- Mohit Parekh (Equal Contribution)
- Gianni Salvalaio
- Hossein Elbadawy
- Stefano Ferrari
- Diego Ponzin
Fondazione Banca degli Occhi del Veneto, Italy
- Vito Romano
Royal Liverpool Hospital, Liverpool, UK
- Massimo Busin
Department of Ophthalmology, Villa Igea Hospital, Forli, Italy