

BANCA DELLE CORNEE REGIONE EMILIA ROMAGNA

SEDE DI IMOLA

Direttore : Dr. Paolo Bonci

Paola Bonci

SIBO in XV congresso nazionale S.I.TRA.C.

Bologna, 24 febbraio 2010

Eur J Ophthalmol. 2010 Nov 3. pii: A93A0734-7818-4B62-BBF3-851439B0D074. [Epub ahead of print]

Deep anterior lamellar keratoplasty with dehydrated, 4 °C-stored, and rehydrated lenticules.

Bonci P, Della Valle V, Bonci P, Lodi R, Russo A.

Department of Ophthalmology, S. Maria della Scaletta Hospital, Imola (Bologna) - Italy.

1966. Eye Exp Res. The thickness-hydration relationship of the cornea. Hedbys BO, Mishima S

1969 South Med. J. Clinical experience using dehydrated corneal grafts in large corneal wounds.

1969 Vestn Ophthalmol. The method of silicodesiccation of the donor cornea and its use in lamellar keratoplasty. Bogdalova RSh-

1972. Archive Klin Exp Ophthalmol. Optimal dehydration of the corneal lamellae for lamellar corneal grafts.

1977 Ophthalmol Zh Use of a silica gel re-dried cornea for a repeated keratoplasty. Goldfeld NG, Fedotov VG, Ionova TA

1978 Clin Oczna. Experimental investigations on the effects of low temperature on corneal changes after corneal dehydration (author's transl). Grabowski J

2006. Cornea. Continuous measurement of corneal dehydration with online optical coherence pachymetry. Aurich H et al.

2001. Br. J. Ophthalmology. Deep lamellare keratoplasty with lyophilised tissue in the management of keratoconus. Coombes A et al.

2003. Yan Ke Xue Bao. The clinical study of 1,267 cases therapeutic keratoplasty using donor corneal grafts in long-time preservation with dehydrated. Zhu X.

2005. Br. J. Ophthalmology. Histopathological and immunohistochemical studies of lenticules after epikeratoplasty for Keratoconus. Nakamura H et al.

2009. Chinese Medical Journal. Effect of prior freezing or drying on the swelling behaviour of the bovine cornea. Huang et al.

LENTICOLI DISIDRATATI

**TRAPANAZIONE DELLA CORNEA
CON PUNCH DELLA MORIA**



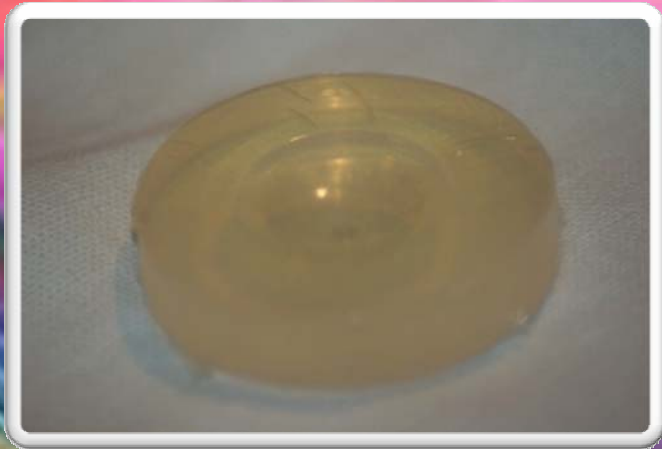**RIMOZIONE MANUALE DELLA
DESCEMET**



**DISIDRATAZIONE LENTICOLI IN
GEL DI SILICE**

TIPI DI SUPPORTO

BASE DI SILICONE (difetto di epitelizzazione centrale)



BASE DI SILICONE RIVESTITA DA TEGADERM difetti riepitelizzazione



BASE DI TEFLON






CARATTERISTICHE ISTOLOGICHE DEL LENTICOLO

STROMA PRIVO DI CHERATOCITI

**RIDUZIONE DELLA MATRICE INTERFIBRILLARE
“collagen free- lakes” (Sayer et al.)**

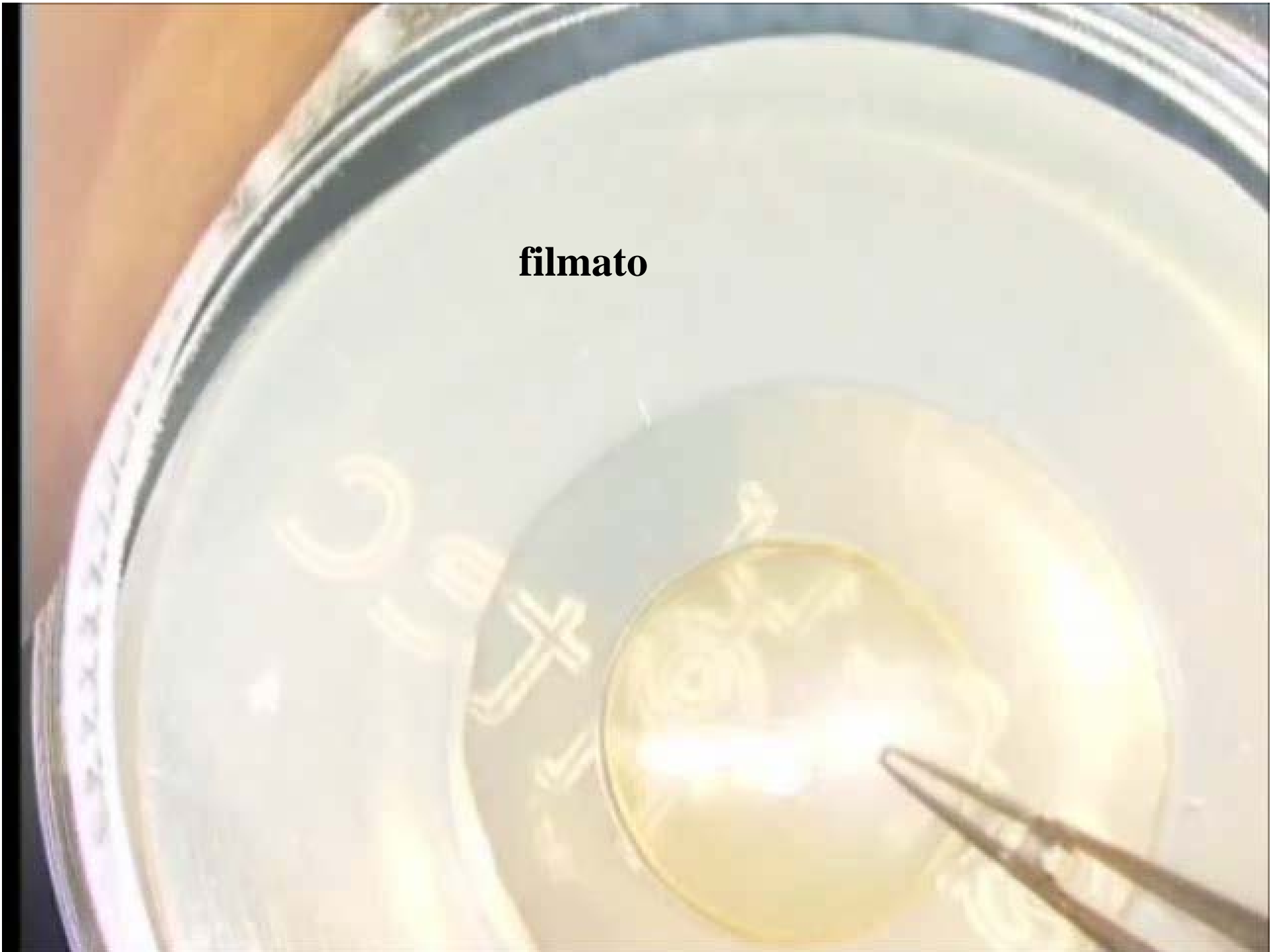**PERDITA DI FLUIDO INTRAFIBRILLARE E RIDUZIONE
DEL DIAMETRO DELLE FIBRILLE. (Meek et al.)**

**MATRICE EXTRACELLULLARE ALTERATA (Hirsch et
al.)**

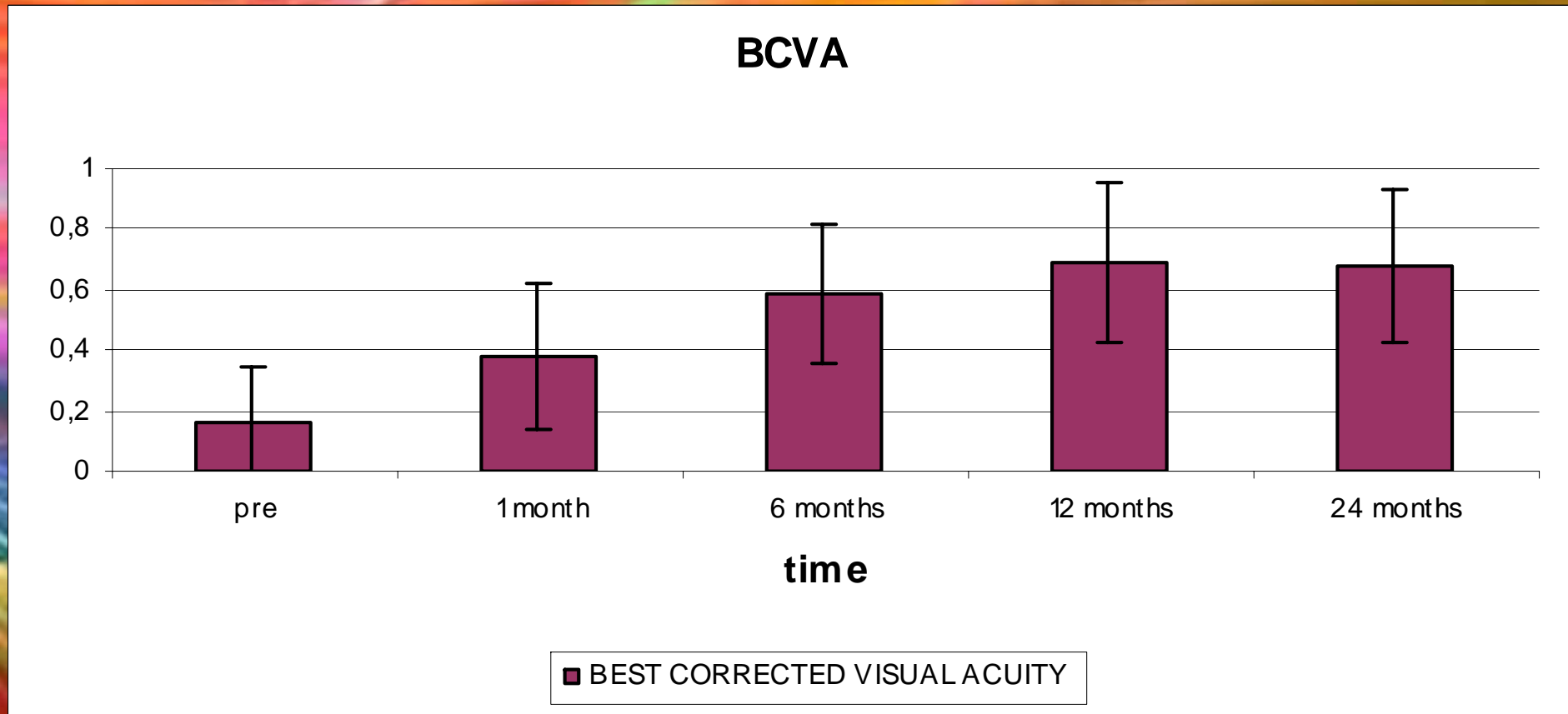


RIPOPOLAZIONE
(microscopia)

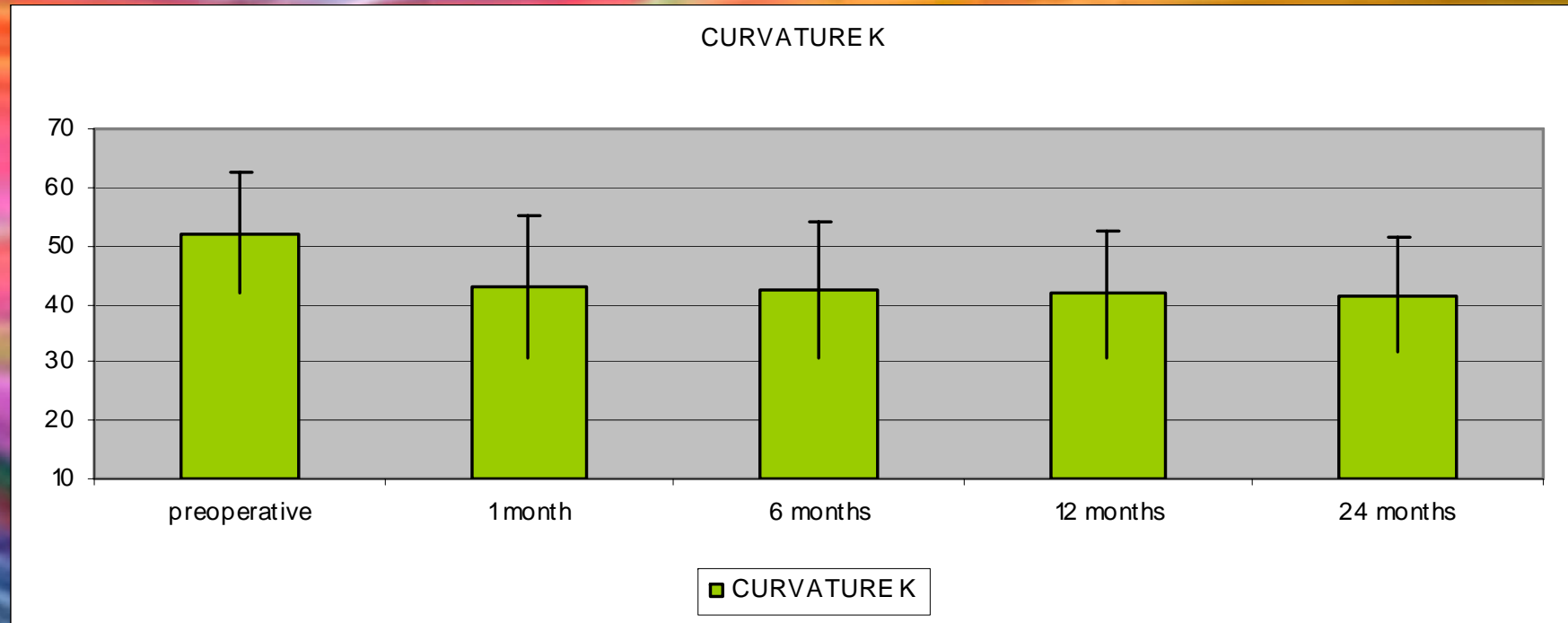
filmato



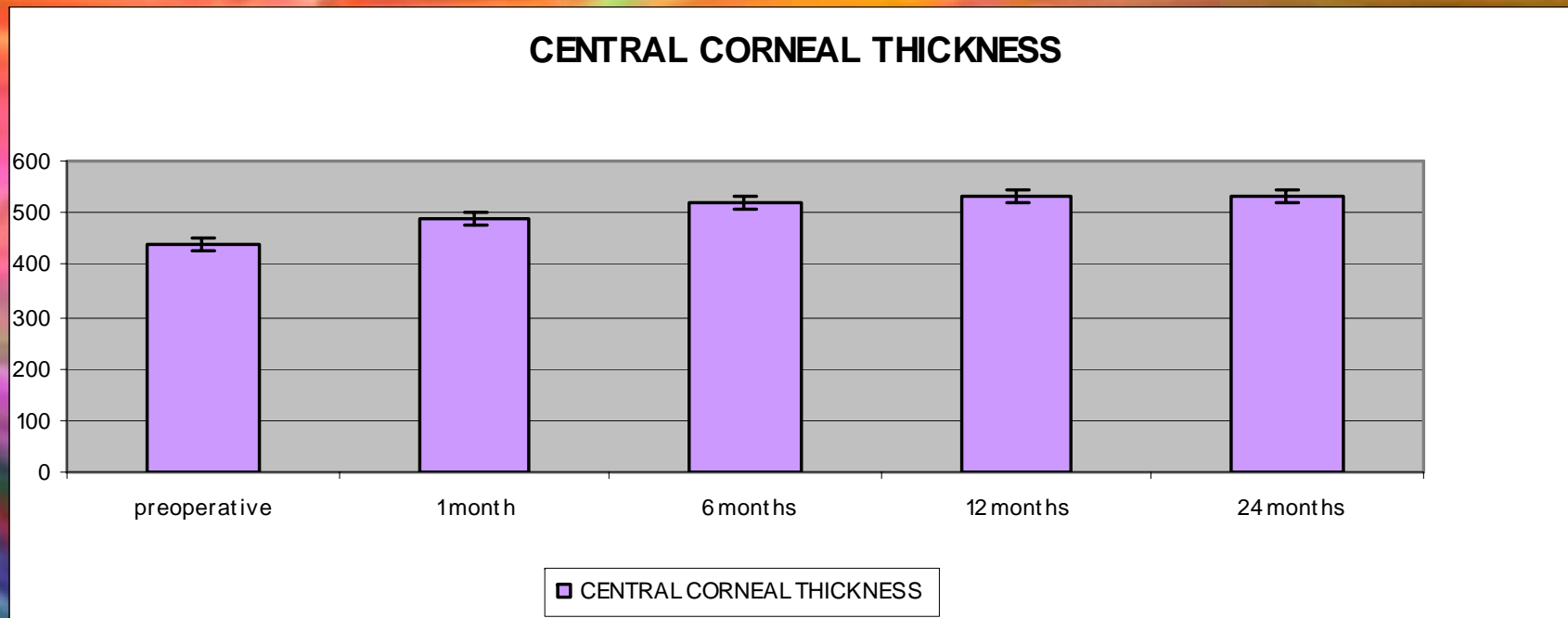
BEST CORRECTED VISUAL ACUITY



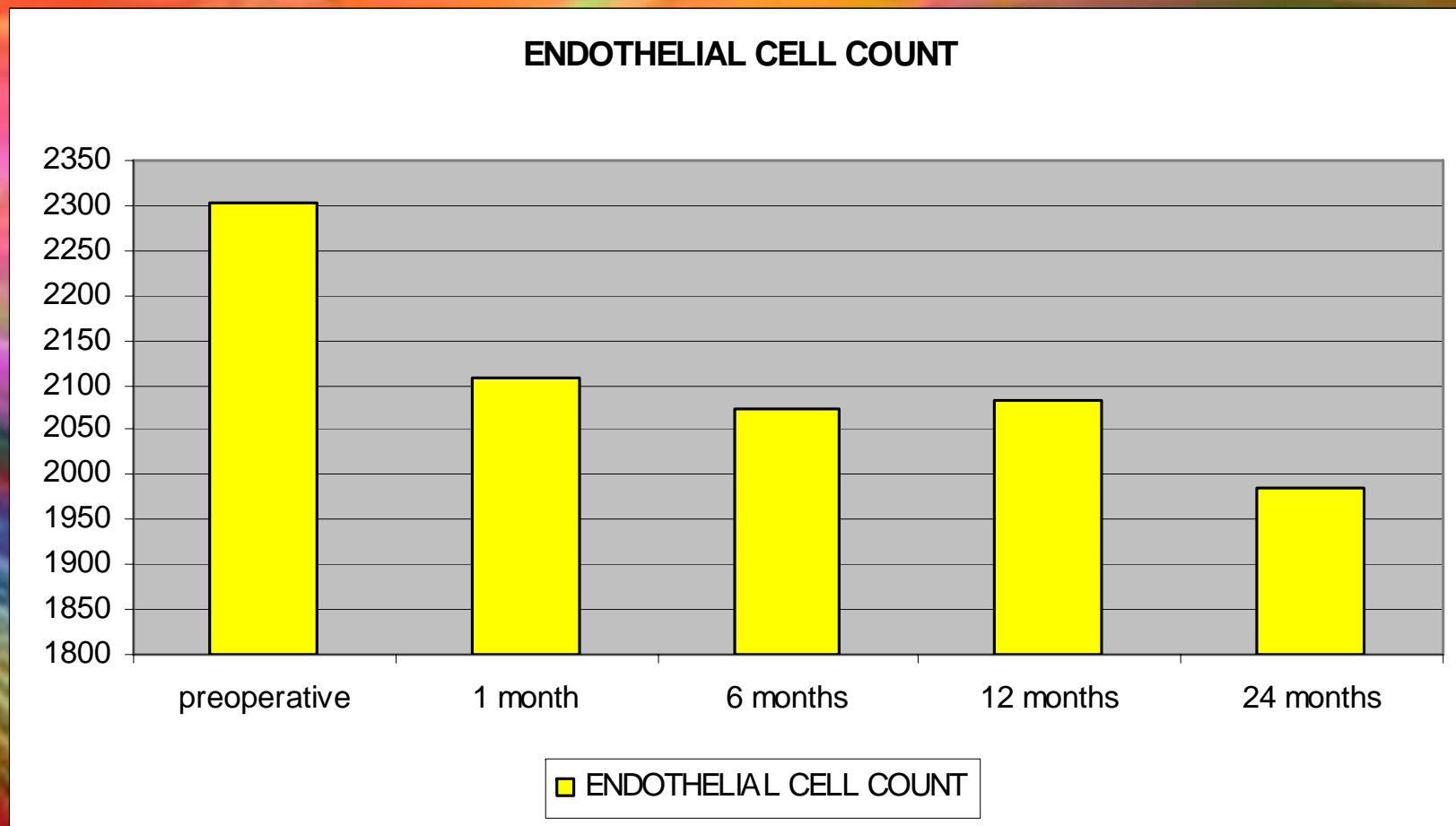
CORNEAL CURVATURE



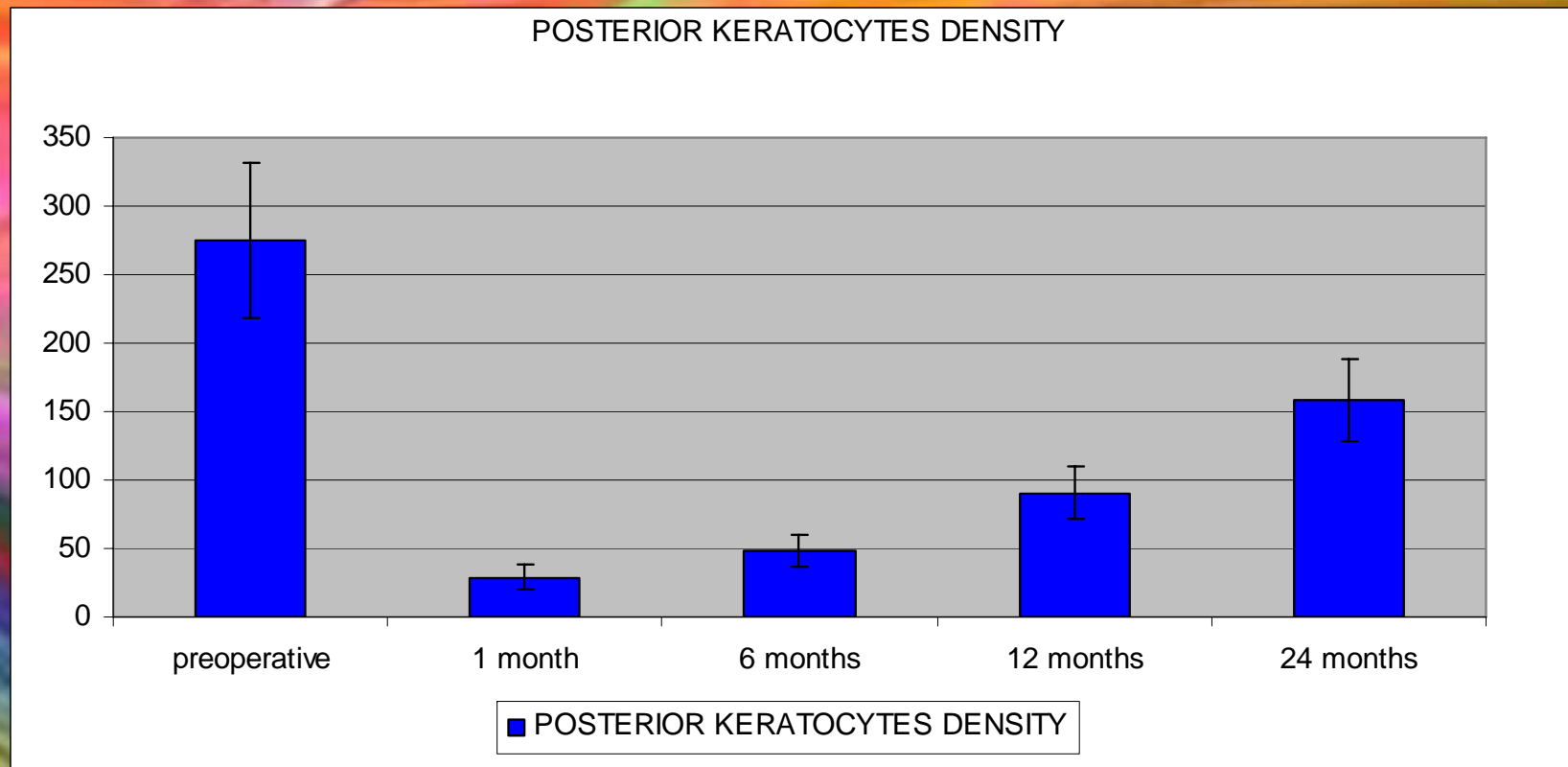
CENTRAL CORNEAL THICKNESS



ENDOTHELIAL CELL COUNT



POSTERIOR KERATOCYTES DENSITY



CONCLUSIONI

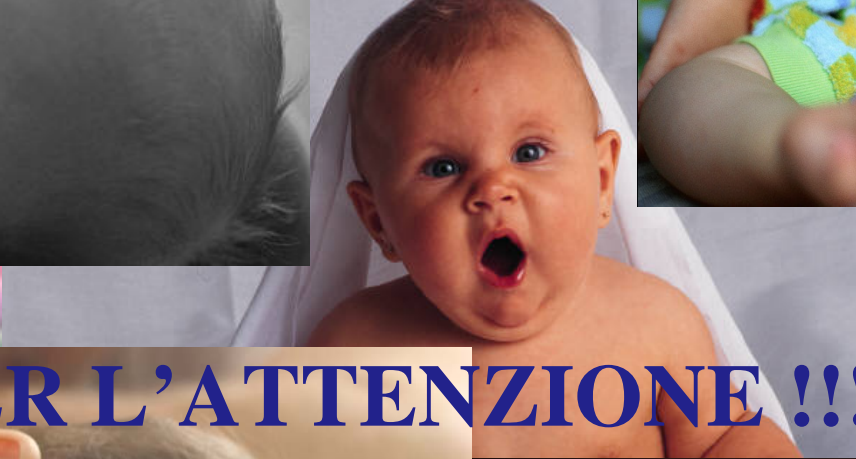•FACILITA' DI PROCESSAZIONE DEL TESSUTO

•STOCCAGGIO PER LUNGHI PERIODI

•CORNEA "READY TO USE" IN QUALSIASI MOMENTO

•MAGGIORE MANEGGEVOLEZZA NELLA PROCEDURA
CHIRURGICA

•RISULTATI SOVRAPPONIBILI A QUELLI OTTENUTI
CON DALK CHE UTILIZZANO CORNEE FRESCHE.



GRAZIE PER L'ATTENZIONE !!!

